

Case report

Pilomatrix carcinoma of face; a case report

Hayat AL-Khasawneh ¹. Shefaa Al-Mashagbah¹. Deifallah AL-Sharari ¹

Olaa AL-Waqfi ¹. Jehad AL-Assaf ¹

1. King Hussein Medical Center, Amman, Jordan

Corresponding author: Hayat AL-khasawneh

Email: Hayat.kh80@yahoo.com

Abstract

Pilomatrix carcinoma is an exceedingly rare malignant tumor derived from hair follicle. Although it has been described at various anatomical sites, fewer than 25 cases have been reported in the face and scalp. The diagnosis of pilomatrix carcinoma is based on histological examination of skin biopsy. . We report a case of pilomatrix carcinoma in an 85 year old male patient presented with cheek nodule.

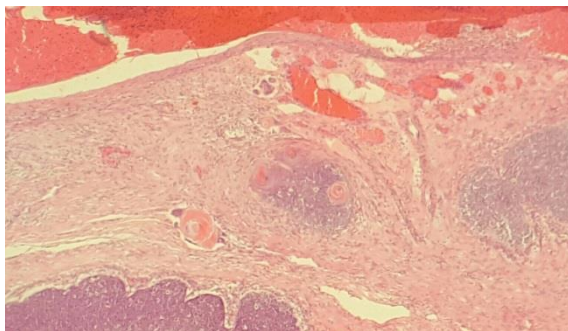
Keywords: *pilomatrix carcinoma.*

Introduction

Pilomatrix carcinoma was described in 1880 by Malherbe(1), is a rare and malignant adnexal tumor. It is still unclear whether de novo arise or it is a malignant transformation in the more common benign counterpart pilomatrixoma. It has been described at various anatomical sites, but less than 25 cases have been reported in the face and scalp(2).

Case report

An 85 year old male patient presented with cheek skin nodule of one year duration. There was no history of previous trauma. The clinical differential diagnosis were basal cell carcinoma versus Merkle Figure 1



cell tumor. We received a skin ellipse measuring 4.0x2.5x0.7cm, bearing a nodule measuring 1.5x1.0cm, showing a central ulceration.

Haematoxylin and Eosin sections studied showed a dermal tumor covered by ulcerated epidermis (figure 1). The tumor composed infiltrative islands of basaloid cells with scanty cytoplasm and indistinct cell borders.

These islands of tumor cells showed central eosinophilic areas of abrupt keratinization containing ghost cells and focal squamous differentiation. Foci of necrosis and increased mitoses were also noted (figure 2)

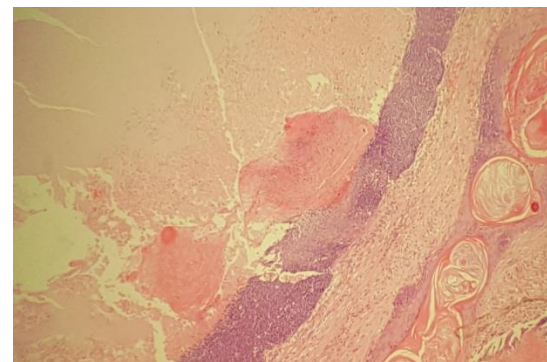


Figure 2

The basaloid cells were immunoreactive for Bcl-2 and B-catenin (nuclear and cytoplasmic) Figure 3. Based on these findings, histopathological diagnosis of pilomatrix carcinoma was given.

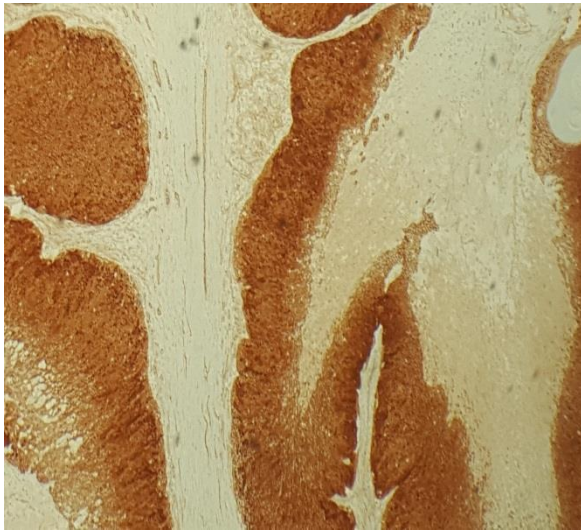
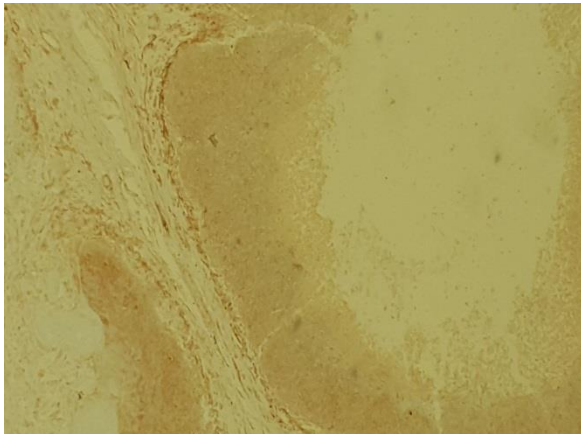
Figure 3. β -catenin positivity

Figure 4. Bcl-2 positivity

Discussion

Malherbe was described Pilomatrix carcinoma for the first time in 1880 as a “calcifying epithelioma” (1) but the malignancy has been known only since 1927 by Gromiko(3). Since then approximately 90 total cases have been reported, 24 of these were in the face and scalp. (2)

Pilomatrix carcinoma is a low-grade malignancy, with a high recurrence rate (46-60%) in the absence of adequate margins. Nodal or systemic metastases are uncommon. Malignant transformation of pilomatrixoma is rare (4,5,6).

Pilomatrix carcinomas occur mostly in middle-aged patients, with an average age of 45 to 60 years old. There is a male predominance (male:female ratio of 1,3,4,5). They may be presented as asymptomatic slow-growing nodule, rapidly enlarging new nodule, or new rapid growth in a long-standing nodule. There is variability in size, with the largest tumour reported measuring 20 cm. (6)

Activating mutations in exón 3 of the CTNNB1 gene, which encodes β -catenin, are detected. The presence of a common mutation implies a common initial pathogenesis(7), so β -catenin immunostain has a role in the diagnosis.

Histologically, the tumor showing eosinophilic ghost cells and basaloid cells at the periphery. Keratinization, and calcium deposits are frequently seen. These features are also seen in pilomatrixoma, but there are histological features help in the diagnosis of pilomatrix carcinoma including; infiltrative pattern, nuclear atypia, increase mitoses with atypical form, areas of massive necrosis, transition to squamous cells, sarcomatoid features and sometimes perineural, and/or vascular invasion. We should keep in mind that brisk mitotic activity is a common feature in early benign lesions and it is not enough to raise the suspicious of malignancy. (4) The treatment is aggressive wide local excision with histologically confirmed negative margins.(5)

Conclusion

Pilomatrix carcinoma is a very rare malignant tumor. The histological features as necrosis, nuclear atypia, infiltrative pattern and atypical mitosis accompanied with B- catenin immunomarker are important to establish the diagnosis and differentiate it from the benign counterpart pilomatrixoma and other differential as basal cell carcinoma, squamous cell carcinoma or trichoepithelioma.

References

1. Alcántara-González, Javier Sánchez-Largo, María Elena, (2014) Pilomatrix carcinoma: a rare cause of facial tumor.
2. Victor M. Duarte, Ali R. Sepahdari, Pilomatrix Carcinoma of the Head and Neck: Case Report and Review of the Literature. International Journal of Otolaryngology and Head & Neck Surgery, 2012, 1, 53-56.
3. D Kotasthane, V Kotasthane, G Koteeswaran. Pilomatrix Carcinoma At The Popliteal Fossa: A Case Report With A Review Of The Literature. The Internet Journal of Pathology. 2012 Volume 13 Number 3.
4. Eluecque H1, Gisquet H, Kitsiou C. Pilomatrix Carcinoma: A Case Report. Eluecque et al., J Clin Exp Dermatol Res 2012, 3:3.
5. B R Sathykrishna, R Wadikhaye, P Sutradhar. Malignant Pilomatrixoma over Left Shoulder: A Case Report. IJSS Case Reports & Reviews | July 2015 | Vol 2 | Issue 2.
6. CC Liu, M Hoy, TW Matthews, K Guggisberg. Pilomatrix carcinoma of the head and neck: Case report and literature review. Head Neck Oncol 2014 May 03;6(2):12.
7. Lazar AJ, Calonje E, Grayson W, Dei Tos AP, et al. Pilomatrix carcinomas contain mutations

in CTNNB1, the gene encoding beta-catenin. J Cutan Pathol 2005;32:148-57 [PMID:15606674].